

## Case Report

# First case of prophylactic salpingectomy with single port access laparoscopy and a new diode laser in a woman with BRCA mutation



S. Angioni<sup>a,\*</sup>, V. Mais<sup>a</sup>, A. Pontis<sup>a</sup>, M. Peiretti<sup>a</sup>, L. Nappi<sup>b</sup>

<sup>a</sup> Division of Gynecology and Obstetrics, Department of Surgical Sciences, Division of Obstetrics and Gynecology, University of Cagliari, Italy

<sup>b</sup> Division of Gynecology and Obstetrics, Department of Medical and Surgical Sciences, Institute of Obstetrics and Gynecology, University of Foggia, Italy

## ARTICLE INFO

## Article history:

Received 15 April 2014

Accepted 13 May 2014

Available online 19 May 2014

## Keywords:

Diode laser

Single port access laparoscopy

Prophylactic salpingectomy

## Introduction

Women who have a BRCA1 mutation have a 39% to 46% risk of developing ovarian cancer by age 70, while women with a BRCA2 mutation carry a 10% to 27% risk by age 70 (Kurman and Shih, 2008). Bilateral salpingo-ovariectomy (BSO) is suggested to BRCA mutation carriers between the ages of 35 and 40, or when childbearing is complete (National Comprehensive Cancer Network, 2013). To reduce the surgical adverse effect of early menopause in young patients many centers have investigated the possible role of bilateral salpingectomy and delayed ovariectomy in preventing ovarian cancer (Anderson et al., 2013). Nevertheless, the effects of salpingectomy on ovarian functions are still controversial but, in any case surgery should be performed avoiding any possible damage to ovarian vascularization. Single-port access laparoscopic (SPAL) surgery has been introduced into the field of minimally invasive surgery and implemented in gynecologic procedures (Angioni et al., 2011, 2010). The main advantage of SPAL surgery is the excellent cosmetic outcome (Song et al., 2013). This approach requires only one umbilical incision; therefore, the surgical scar can be hidden within the umbilicus, making the surgery virtually scarless. In addition to the potential cosmetic benefits, other theoretical advantages of SPAL surgery compared to conventional laparoscopy include less postoperative pain and a faster recovery (Mencaglia et al., 2013). Recently, an exponential growth in the use of diode lasers has been observed in almost every area of pure and applied sciences; a wide variety of the semiconductors propelled the invention of a variety of

diode lasers that opened several new way researches. Different types of lasers have been used over time, including Argon, CO<sub>2</sub>, Yag, diode 810 and others. The currently available 980 + 1470 Nm diode laser may have certain advantages. A diode is an electronic laser consisting of 2 semiconductor materials with the size of a grain of sand. This technology makes it possible for this laser to be the smallest available. A microprocessor-controlled system regulates the flow of electrical current through the diode and generates the laser beam allowing cutting and coagulating with very low lateral thermal damage.

We report the first case of single port laparoscopy with use of a diode laser for bilateral salpingectomy in a patient with BRCA1 and BRCA2 mutation.

## Case report

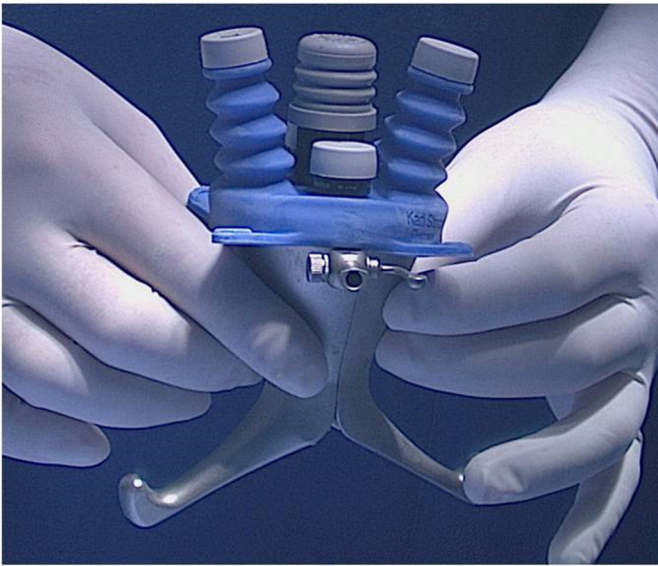
A 38-year-old, nullipara woman with two family cases of breast cancers. Genetic analysis of patient showed the BRCA1 mutation (c.981\_982 delAT). Gynecologic examination was regular. Ultrasound examination showed corpus uterus antiversio of 37 × 28 × 41 mm, inhomogeneous myometrial echo texture, endometrial thickness of 3 mm, and regular bilateral ovaries and fallopian tubes. Endometrial cytology and endometrial biopsy showed no alterations. The patients reported a history of infertility related to male factor and refused ovariectomy. An informed consent was obtained after discussing risks and benefits of a single port laparoscopy approach and use of laser a diode for bilateral salpingectomy for the prevention of tubal cancers and possibly the prevention of ovarian cancers.

A reusable single site trocar with 5 integrated access ports was used (S-Portal X-Cone; Karl Storz, Tuttlingen, Germany). This device consists of two symmetrical metal half shells that are connected and sealed by one large silicon cap containing the access ports (Fig. 1).

Following the induction of general anesthesia, the patient was placed in the dorsal lithotomy position with both legs supported in stirrups with a Trendelenburg tilt. An open technique was used to gain access to the abdomen and X-Cone trocar was placed through a 20 mm fascial incision. Once pneumoperitoneum was achieved (12 mm Hg), intra-abdominal visualization was obtained with introduction of a 5-mm 30 degree laparoscope (Hopkins®, Karl Storz, Germany). A 5-mm sheath bending grasping forceps (Click'line Grasping Forceps; Karl Storz, Tuttlingen, Germany) were inserted to manipulate tissues as previously described (Mereu et al., 2010). To perform bilateral cutting and coagulation of meso-salpinx and of the proximal part of the tubes

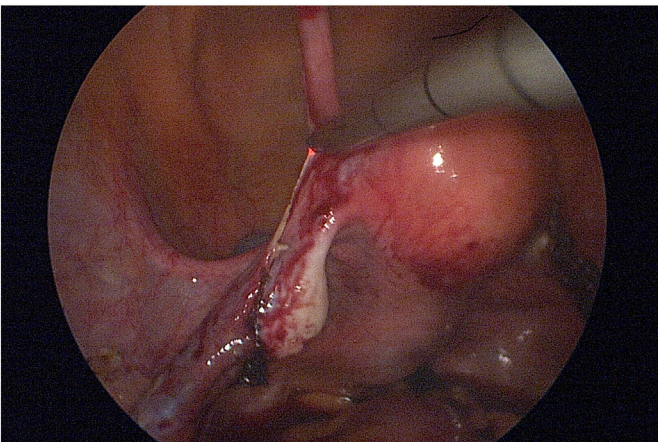
\* Corresponding author at: Department of Surgical Sciences, Division of Obstetrics and Gynecology, University of Cagliari, S.S. 554, Monserrato, Italy.

E-mail address: [sangioni@yahoo.it](mailto:sangioni@yahoo.it) (S. Angioni).



**Fig. 1.** Multiport single access laparoscopic trocar S-Portal X-Cone (Karl Storz, Tuttlingen, Germany).

we used a new Dual wavelengths Laser System (D.w.L.S.; Leonardo®, Biolitec, Germany) to generate a 980-+1470 nm laser through a diode semiconductor (Fig. 2). A 1000  $\mu\text{m}$  fiber with an atraumatic conic tip at the distal end was inserted in a dedicated laparoscopic sheath that has an external diameter of 5 mm and is suitable for standard trocars. The sheath is designed to be used with laser fibers of  $\varnothing$  600–1000  $\mu\text{m}$  and has a length of 40 cm. A bilateral salpingectomy was performed and fallopian tubes were easily removed separately with an endobag, introduced through the 12-mm central port of the X-Cone. Suture of the fascia was performed to prevent hernia formation (Vicryl 0, single stitches). Closure of the cutaneous wound and reconstruction of the umbilical shape was performed with absorbable single stitches. The duration of the procedure was 40 min. Pain score measured immediately after surgery in the recovery unit was 3. The postoperative pain scores after 6, 24 and 48 h were 3, 2 and 1, respectively. The patient received a painkiller only 6 h after surgery. No intraoperative and postoperative complications were observed. The patient was discharged the day after surgery. Pathological analysis revealed regular fallopian tube histology. Excellent cosmetic outcome was obtained at 1 month follow-up.



**Fig. 2.** Diode laser salpingectomy.

## Discussion

The cell of origin of ovarian cancer and the mechanisms by which cancer develops have been long debated. Actually, there is mounting evidence that type I and type II ovarian tumors develop independently along different molecular pathways, and that both types develop in the fallopian tube and involve it secondarily (Kurman and Shih, 2008). Salpingectomy alone may be sufficient to accomplish this, as removal of the fallopian tubes would reduce the risk of ovarian cancer while preserving ovarian function (Anderson et al., 2013; Holman et al., 2014). Ovarian conservation seems to be particularly important for a woman's health, as it has been shown that oophorectomy is associated with increased overall mortality and a higher frequency of nonfatal coronary heart disease. Minimally invasive surgery should be performed in order to achieve faster recovery and good cosmetic outcomes. Single port laparoscopy is an attempt to further enhance the cosmetic benefits of laparoscopy surgery while minimizing the potential morbidity associated with multiple incisions. The intrinsic limit of this new approach that should be taken into consideration is that it offers fewer degrees of freedom between the instruments, thus limiting the surgeon's movements, the surgical ergonomics, and hence increasing operating time. In this context, the utilization of specific instruments and some cautions should be considered to improve the performance of surgery (Mereu et al., 2010). The diode laser has also recently been used in minimally invasive surgery. It induces excellent hemostasis as a result of the high absorption in melanin and hemoglobin in the near-infrared portion of the spectrum. The diode laser can be used in direct contact with tissue (contact mode) or at a distance from tissue (non-contact mode). In contact mode, the fiber tip is coated with a thin layer of carbon. The heated tip can then be used to incise, excise, and coagulate tissue while a zone (0.3–0.6 mm) of thermocoagulation provides excellent hemostasis of vessels up to 2 mm in diameter. In contrast to the CO<sub>2</sub> laser, the diode laser is more often used in contact mode with minimal tissue penetration of only 0.3–0.6 mm. The laser beam is transmitted from the base unit to the surgical site by a solid quartz-core, fiber-optic cable. A visible red light beam is combined with the invisible laser beam allowing an extreme accurate cutting and coagulation. Laser fibers come in a variety of sizes (400–1000  $\mu\text{m}$ ) and shapes, including flat, conical, and orb tips and air- or water-cooled. The fibers may be used through the instrument channel of a variety of rigid and flexible endoscopes. Its use in gynecology has been described for salpingostomy and treatment of endometriosis with biopsy and cauterization with an excellent surgical outcome and no complication (Abrao et al., 2000).

In single port surgery diode laser could be very useful as it consent to cut and coagulate without changing instruments with extreme precision and minimal thermal damage and surgical time saving. Surgical specimens can be evaluated by the pathologist without any anatomical distortion that could happen sometime using bipolar coagulation. In particular, in BRCA carriers with programmed salpingectomy and delayed ovariectomy, the accurate evaluation of the fimbriae and of the tubes epithelium histology is mandatory to evidence any possible initial neoplastic disease. Nevertheless, the preservation of ovarian vascularization that is almost certain by the use of D.w.L.S. is very important in young patients.

In conclusion, this is the first case of the use of diode laser to perform prophylactic salpingectomy in high risk patients desiring to delay ovariectomy by single port access laparoscopy. This approach has the potential to offer fast recovery, good cosmetic outcome, preservation of ovarian function and optimal surgical specimen for pathological investigation.

## Conflict of interest statement

Authors declare that they have no conflict of interest.

## References

- Abrao, M.S., Ikeda, F., Podgaec, S., Pereira, P.P., 2000. Microlaparoscopic for an intact ectopic pregnancy and endometriosis with the use of a diode laser: case report. *Hum. Reprod.* 15 (6), 1369–1371.
- Anderson, C.K., Wallace, S., Guiahi, M., Sheeder, J., Behbakht, K., Spillman, M.A., 2013. Risk reducing salpingectomy as preventative strategy for pelvic serous cancer. *Int. J. Gynecol. Cancer* 23, 417–421.
- Angioni, S., Maricosu, G., Mereu, L., Mencaglia, L., Melis, G.B., 2010. Single Port Access Laparoscopy (SPAL) for endometrioma excision. *J. Endometriosis Pelvic Pain Dis.* 2 (2), 95–98.
- Angioni, S., Maricosu, G., Mereu, L., Mencaglia, L., Melis, G.B., 2011. Single-port access laparoscopic assisted vaginal hysterectomy in a case of uterine ventrofixation using a new reusable device. *J. Obstet. Gynaecol. Res.* 37 (7), 933–936.
- Holman, L.L., Friedman, S., Daniels, M.S., Sun, C.C., Lu, K.H., 2014. Acceptability of prophylactic salpingectomy with delayed oophorectomy as risk-reducing surgery among BRCA mutation carriers. *Gynecol. Oncol.* <http://dx.doi.org/10.1016/j.ygyno.2014.02.030> (pii:S0090-8258(14)00148-6).
- Kurman, R.J., Shih, IeM, 2008. Pathogenesis of ovarian cancer: lessons from morphology and molecular biology and their clinical implications. *Int. J. Gynecol. Pathol.* 27 (2), 151–160.
- Mencaglia, L., Mereu, L., Carri, G., Arena, I., Khalifa, H., Tateo, S., Angioni, S., 2013. Single port entry—are there any advantages? *Best Pract. Res. Clin. Obstet. Gynaecol.* 27 (3), 441–455.
- Mereu, L., Angioni, S., Melis, G.B., Mencaglia, L., 2010. Single access laparoscopy for adnexal pathologies using a novel reusable port and curved instruments. *Int. J. Gynaecol. Obstet.* 109 (1), 78–80.
- National Comprehensive Cancer Network, 2013. Genetic/Familial High-risk Assessment: Breast and Ovarian. NCCN Clinical Practice Guidelines in Oncology V12013, NCCN, Fort Washington (PA).
- Song, T., Choi, J., Kim, T.J., Kim, I.R., Hahm, T.S., Kim, B.G., Bae, D.S., 2013. Cosmetic outcome of laparoendoscopic single-site hysterectomy compared with multi-port surgery: randomized controlled trial. *J. Minim. Invasive Gynecol.* 20 (4), 460–467.